



Roof Rats: Pathogens and Parasites

For Pest Management Professionals and Environmental Health Professionals

Dawn H. Gouge, Paula Rivadeneira and Shujuan (Lucy) Li

Introduction

The roof rat (Figures 1 & 4 *Rattus rattus*), also known as the black rat, ship rat, or house rat, is an Old World rodent species originating in southeast Asia. Although it is not native to North America, roof rats are established in most coastal and southern states in the continental United States (U.S.), Hawaii, and small populations exist in Alaska. Information covering the identification, ecology, and signs of roof rats are covered in a separate publication by the same authors (<https://extension.arizona.edu/sites/extension.arizona.edu/files/pubs/az1775-2018.pdf>).

Roof rats pose a significant health and safety hazard as they are implicated in the transmission of a number of diseases to humans and domesticated animals. These diseases include leptospirosis, salmonellosis (food contamination), rat-bite fever, murine typhus, plague, toxoplasmosis, and trichinosis.

Roof rats in Arizona may carry ectoparasites that pose a threat to human health via bites from the ectoparasites; such ectoparasites include the Oriental rat flea (*Xenopsylla cheopis*), the tropical rat mite (*Ornithonyssus bacoti*), spiny rat mite (*Echinolaelaps echidninus*), the spiny rat louse (*Polyplax spinulosa*), and tropical rat louse (*Hoplopleura pacifica*) (Table 1). In most instances, people report skin irritation and itching because of ectoparasite bites, but some of the ectoparasites can have more serious effects, including vectoring disease-causing pathogens to people. Ectoparasites may also be transferred from roof rats to domestic pets, and in the case of the Oriental rat flea, they may be transferred from roof rats onto pet rodents and rabbits.

While the Oriental rat flea is the natural ectoparasitic flea of roof rats, many other species are found. This includes the northern rat flea (*Nosopsyllus fasciatus*), especially where roof rats and Norway rats (*Rattus norvegicus*) occur in the same environment. Additionally, dog fleas (*Ctenocephalides canis*), cat fleas (*Ctenocephalides felis*), and sticktight fleas (Figure 2 *Echidnophaga gallinacea*) are all found on roof rats, sometimes



Figure 1. *Rattus rattus* by Alex O'Neal (CC BY-SA 2.0)



Figure 2. Sticktight flea (*Echidnophaga gallinacea*) on a Norway rat by James Campbell, California State Polytechnic University, Pomona

in larger numbers than Oriental rat fleas. Similarly, a variety of mites may utilize rats as hosts.

Both the ectoparasites and pathogens carried by a specific roof rat population are influenced by their immediate environment. Very little is known about roof rat populations in Arizona or the health risks they pose.

Leptospirosis

Leptospira bacteria are one of the most common causes of disease transmitted to people from wild and domestic animals, including cattle, pigs, horses, and dogs. They cause a wide range of symptoms, though some animals and some people may not develop symptoms at all.

Illnesses caused by *Leptospira* are known by many names, including: Weil's syndrome, canicola fever, canefield fever, nanukayami fever, 7-day fever, Rat Catcher's Yellows, Fort Bragg fever, black jaundice, and Pretibial fever. Symptoms in humans may include high fever, severe headache, chills, muscle aches, vomiting, jaundice, red eyes, abdominal pain, diarrhea, and/or a rash. In the absence of treatment, kidney damage, meningitis (inflammation of the membrane around the brain and spinal cord), liver failure, and respiratory distress can be severe, and in rare cases the infection may be fatal.

Humans most commonly contract an infection through contact with urine or other bodily fluids (except saliva) from infected animals, or contact with water, soil, or food contaminated with the urine of infected animals. *Leptospira* bacteria in water or soil can survive for weeks to months. The bacteria can enter the body through mucous membranes (eyes, nose, or mouth), and broken skin. Drinking contaminated water can also cause infection. Person-to-person transmission is rare.

Salmonellosis (food contamination)

Microbial pathogens of the genus *Salmonella* are among the leading causes of foodborne illness in the world. **Consuming food or water that is contaminated by infected rat feces can lead to disease.**

Commensal rodents are reservoirs for human salmonellosis, and *Salmonella enterica* has been isolated from both roof rats and Norway rats. In the 1990s, *Salmonella enterica* Serovar Typhimurium, definitive phage type 104 (DT104) emerged as a significant problem in Europe and the U.S. because the strain has multidrug resistance. DT104 strains are found internationally in many animal reservoirs.

Salmonella enterica Serovar Typhimurium is rarely fatal. Symptoms include diarrhea, abdominal cramps, vomiting, and nausea that last for about a week. However, the elderly, very young people, or people with depressed immune systems may develop life-threatening infections if they are not treated with effective antibiotics.

Rat-bite fever

Rat-bite fever is a systemic bacterial illness caused by *Streptobacillus moniliformis* in the U.S., and other bacteria in other parts of the world. The bacteria are **transferred to a human through the bite or scratch of an infected rodent, or through the ingestion of food or water contaminated with infected rat feces.** When the latter occurs, the disease is often known as Haverhill fever. If not treated, rat-bite fever can become serious and sometimes fatal.

Streptobacillary rat-bite fever symptoms include fever, vomiting, headache, muscle and joint pain, and a rash. Symptoms usually occur 3-10 days after exposure to an infected rodent, but the onset of illness can be delayed as long as 3 weeks, making the link between rodent exposure and illness less obvious since bite or scratch wounds have often healed by then.

Within 2-4 days after fever onset, a rash may appear on the hands and feet. This rash appears as flat, reddened areas with small bumps. Joints may also become swollen, red, and painful.

Murine typhus

Rickettsia typhi are gram negative, intracellular bacteria and the etiologic agent of murine (also called endemic) typhus. The rickettsial pathogen is transmitted primarily by the Oriental rat flea, although ectoparasitic lice and some mites are also vectors. Commensal rodents, including roof rats and Norway rats, are the main pathogen reservoirs, but other vertebrate hosts serve in the same capacity including house mice, shrews, opossums, skunks, and feral and domestic cats.

Symptoms of murine typhus begin within 2 weeks after contact with infected fleas. Signs and symptoms may include fever and chills, body aches and muscle pain, loss of appetite, nausea, vomiting, stomach pain, cough, and rash. Most people will recover without treatment, but some cases may become severe, potentially causing serious organ damage. Rats do not suffer symptoms from *R. typhi* infection, so rat fleas remain infected and are able to vector the pathogen. **Humans are infected through the bite of a rat ectoparasite,** and although humans contracting murine typhus often report contact with a vertebrate host, few recall seeing fleas or other ectoparasites biting them.

Plague

Plague primarily affects rodents, but can affect other mammals as well, including humans. Plague is caused by *Yersinia pestis*, a non-motile, rod-shaped coccobacillus. It is a facultative anaerobic bacterium. There are around 2,000 human cases of plague globally each year. It is considered a re-emerging disease and remains a serious problem for global public health.

Plague risks increase significantly when people live in close contact with infected rodents that carry high flea numbers. In the U.S., the Centers for Disease Control report that modern day outbreaks of plague usually occur in the southwestern states, including Arizona, California, Colorado, and New Mexico (<https://www.cdc.gov/plague/maps/index.html>).

Humans most often contract plague through the bite of a rodent flea that is carrying the plague bacterium. But the bacterial pathogen can also be contracted through direct contact with an infected animal or person, e.g., through the consumption of insufficiently cooked meat, or inhalation of aerosolized droplets coughed or sneezed from an infected animal or person with the pneumonic form of the infection.

Plague symptoms depend on how the patient was exposed to the bacteria. Plague can take different clinical forms, but the most common are bubonic, pneumonic, and septicemic.

Bubonic plague usually results from the bite of an infected flea. Patients develop sudden fever, headache, chills, weakness, and swollen, painful lymph nodes called buboes. If the patient is not treated with antibiotics, the bacteria can spread to other parts of the body.

Septicemic plague can result from bites of infected fleas or from handling an infected animal. It can occur as the first indication of plague, or it may develop from untreated bubonic plague. Patients develop fever, chills, weakness, abdominal pain, shock, and sometimes bleeding into the skin and other organs. Skin and other tissues may turn black, indicating necrosis.

Pneumonic plague may develop after inhalation of aerosolized respiratory excreta (droplets coughed or sneezed) of animals or people with the pneumonic form of the infection. It may also develop from untreated bubonic or septicemic plague after the bacteria spread to the lungs. Patients develop fever, headache, weakness, and pneumonia with chest pain, cough, and sometimes bloody or watery mucous. Respiratory failure and shock may occur. Pneumonic plague can spread from person to person.

Plague is a serious illness. If the disease is suspected, seek immediate medical attention. Prompt treatment with antibiotics effective against *Yersinia pestis* can prevent complications or death.

Cuterebra spp. - rodent and lagomorph (rabbits and hares) bot flies

Dime and nickel sized warbles (Figure 3) and scars are sometimes found on rodents, made by large bot fly maggots below the skin. The female bot fly lays her eggs in different

locations depending on the species. A typical female will lay one to several thousand eggs, in groups of around 5-15 per site. Some species lay eggs on grass stems, wood chips, and bark along trails and rodent runs near burrows. Eggs hatch in response to increases in temperature when hosts are present. Larvae stick to the host fur and typically enter the host through natural body opening (e.g., mouth, nose, eyes, or anus). First instar maggots migrate through the body and eventually to the subcutaneous positions where the larvae molt to second instar and continue to develop within the developing warble. Third instar larvae back out of the warble and pupate in the soil. Bot flies will lay eggs in pet bedding resulting in infections of dogs and cats, secondary infections commonly follow. The larval stages *Cuterebra* spp. are commonly found in furuncular lesions (small, raised, red, boil-like) in the skin of the rodent host. In cats, the furuncular lesions more commonly show on the cheeks, neck, top of the head, or chest. Larvae have also been reported in the nasal pharynx, pharyngeal area, eye orbits and anterior chamber of the eyes. Intracranial myiasis due to *Cuterebra* has been reported in cats on several occasions, and cats in which larvae migrate through the brain develop neurologic disease. *Cuterebra* spp. have been recovered from humans. Most human cases have occurred in the northeastern U.S. Most larvae are recovered from the head, neck, shoulders and chest. There have been rare cases of bot fly larvae in ocular and upper respiratory areas, but no central nervous system disease has been documented in humans.

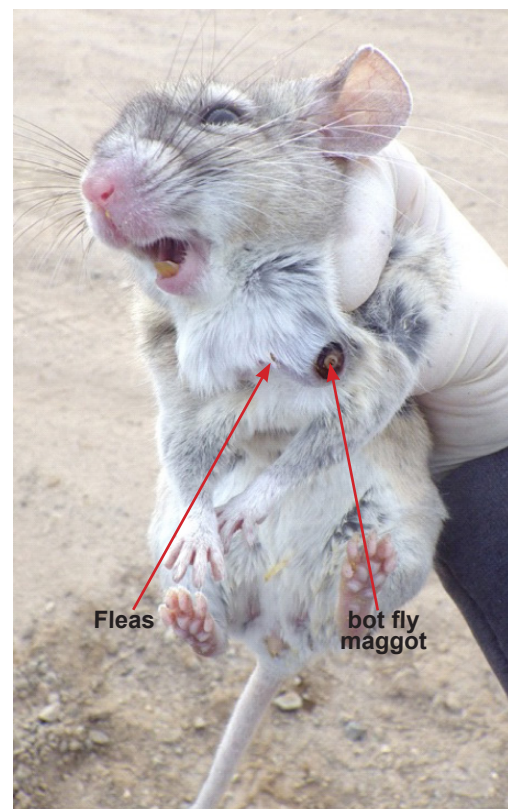


Figure 3. Fleas on and bot fly maggot in a wood rat

Toxoplasmosis

Toxoplasma gondii is an obligate intracellular parasite of warm-blooded animals. Infections usually cause mild flu-like symptoms in adults. Occasionally people may be affected with prolonged illness lasting months that includes muscle aches and tender lymph nodes. Blurred vision develops on rare occasions, and numerous behavioral changes have been associated with human and rat infections. In those with a weak immune system, severe symptoms such as seizures and poor coordination may occur. In infants and those with compromised immunity, the infection may cause a serious and life-threatening illness. If infected during pregnancy, a condition known as congenital toxoplasmosis may affect the infant.

Humans are infected most commonly through eating undercooked or contaminated meat. They may also be exposed through drinking contaminated water, or by accidentally ingesting the parasite through contact with cat feces that contain *Toxoplasma*. Cats acquire *Toxoplasma* by eating rats and mice that carry the disease and the oocysts (eggs) survive in their feces. Therefore, people may be exposed to *Toxoplasma* while cleaning an infected pet cat's litter box, or by coming into contact with contaminated cat feces, soil where cat feces were introduced, or unwashed fruits or vegetables from a garden where cat feces were present.

Trichinosis

Trichinellosis (trichinosis) is caused by *Trichinella* nematodes. Symptoms in humans initially include nausea, diarrhea, vomiting, fatigue, fever, and abdominal discomfort. Headaches, fevers, chills, cough, swelling of the face and eyes, aching joints and muscle pains, itchy skin, diarrhea, or constipation follow the first symptoms. If the infection is severe, patients may experience difficulty coordinating movements, and have heart and respiratory problems, and in some cases, death can occur. For mild to moderate infections, most symptoms subside within a few months. Fatigue, weakness, muscle pain, and diarrhea may last for months.

Rats and other rodents are responsible for maintaining the infection. Carnivorous and omnivorous animals, such as pigs, wild boar, bears, and cougar that have fed on infected rodents or meat from other animals can develop active infections. **Humans are accidentally infected when eating improperly cooked or processed meat of infected animals (or eating food contaminated with such meat).**

Nematode infections

There have been rare cases of people contracting rat lungworms. *Angiostrongylus cantonensis* is a parasitic nematode of roof rats that causes angiostrongyliasis. They are the most common cause of human eosinophilic meningitis in Southeast Asia and the Pacific Basin. The nematode resides in the pulmonary arteries of rats, giving it the common name rat lungworm. The parasite has been confirmed in Arizona, California, Colorado, Utah, Texas,

Alabama, New York, and Tennessee, but it is likely to be present elsewhere also.

Humans are typically infected when snails and slugs carrying the infection are inadvertently ingested.

Capillaria hepatica is a parasitic nematode that causes hepatic capillariasis in rodents and numerous other mammal species, including humans. Humans are usually infected after ingesting embryonated eggs in fecal-contaminated food, water, or soil. Occasionally in humans, larvae will migrate to the lungs, kidneys, or other organs. The presence of *C. hepatica* eggs in human stool during routine ova-and-parasite examinations indicates passage of ingested eggs through the gut, and not a serious infection of the body.

Ticks

Ectoparasites found on roof rats belong to four different groups: fleas, lice, mites, and ticks (see table 1). While several species of ticks in the family Ixodidae are found on roof rats in other parts of the world, very little is currently known about urban roof rats' association with ticks in Arizona.

Rabies

Wild rats of any species have never caused rabies in humans in the U.S., and rarely do so in other countries. Rats are therefore not considered a serious rabies risk, and rabies prophylaxis is not considered necessary after a rat bite.

Hantavirus Pulmonary Syndrome and Seoul Virus






Roof rats have never been implicated in a human hantavirus incidence, and are not considered a hantavirus reservoir species. However, roof rats have been associated with Seoul virus that is a member of the hantavirus family of rodent-borne viruses (Bunyaviridae family). Most people who contract Seoul virus experience mild or no symptoms, but those developing the severe form of the disease, exhibit hemorrhagic fever with renal syndrome which can be deadly. Seoul virus has been isolated in many states across the U.S. in both 2017 and 2018, and Seoul virus from pet rats to humans has been documented in the U.S.

Roof rats cause human illness both directly and indirectly and should not be tolerated inside inhabited buildings.

Over several decades there has been a consistent and significant increase in the geographic host ranges of many vector-borne pathogens and related diseases. Range expansion has been driven by climate change and human encroachment into wild habitats. Relatively little research is focused on rat populations in urban areas, but increasing health risks have been confirmed in some U.S. cities.

Information about controlling roof rats is available in a publication entitled Roof Rats: Integrated Rodent Management by the same authors.

Table 1. Roof rat ectoparasites

Ectoparasite		Human disease
<p>Oriental rat flea <i>Xenopsylla cheopis</i></p> <p>Adults are hard-bodied (difficult to crush between fingers), light to dark brown coloration, 1.5 to 4 mm in length with three pairs of legs.</p>	 <p>By Olha Schedrina / The Natural History Museum - http://data.nhm.ac.uk/object/c11c05ab-189f-4a19-826f-873bbd04b3c6</p>	<p>Primary vector for <i>Yersinia pestis</i> (plague) & <i>Rickettsia typhi</i> (murine typhus)</p> <p>Flea bites can be very itchy and painful. Hives and some swelling near the site of a bite may occur.</p>
<p>Tropical rat mite <i>Ornithonyssus bacoti</i></p> <p>Mean length and breadth of adult female mites 1 mm × 0.6 mm. The body is hairy and has four pairs of legs.</p>	 <p>By Erling Ólafsson Rottumífill <1 mm. ©EÓ</p>	<p>Rat mite dermatitis</p>
<p>Spiny rat mite <i>Echinolaelaps echidninus</i></p> <p>Adult females are oval, and almost covered with a sculptured dorsal shield. The body is about 1 mm long and 0.7 mm wide and has four pairs of legs.</p>	 <p>By Matt Frye, New York State Integrated Pest Management, Cornell University</p>	<p>Rat mite dermatitis</p>
<p>Spiny rat louse <i>Polyplax spinulosa</i></p> <p>Adult females have elongated flattened bodies dorsoventrally 1-1.5 mm in length and have three pairs of legs.</p>	 <p>By Matt Frye, New York State Integrated Pest Management, Cornell University</p>	<p>Do not bite humans but may be intramurid vectors of murine typhus and other zoonoses.</p>
<p>Tropical rat louse <i>Hoplopleura pacifica</i></p> <p>Adult females have elongated flattened bodies dorsoventrally <1 mm in length and have three pairs of legs.</p>	 <p>By K.C. Emerson Entomology Museum, Stillwater Oklahoma</p>	<p>Do not bite humans but may be intramurid vectors of murine typhus and other zoonoses.</p>

Acknowledgement

This material is based upon work that is supported in part by the National Institute of Food and Agriculture, U.S. Department of Agriculture (USDA NIFA), under award number 2017-70006- 27145, which provides Extension IPM funding to University of Arizona. Any opinions, findings, conclusions, or recommendations expressed in this publication are those of the authors and do not necessarily reflect the view of the U.S. Department of Agriculture. Additional support is provided by the University of Arizona – Arizona Pest Management Center (APMC).



Figure 4. *Rattus rattus* by Alex O'Neal (CC BY-SA 2.0)



THE UNIVERSITY OF ARIZONA
Cooperative Extension

THE UNIVERSITY OF ARIZONA
COLLEGE OF AGRICULTURE AND LIFE SCIENCES
TUCSON, ARIZONA 85721

DAWN H. GOUGE

Specialist and Professor - Public Health Entomologist, Department of Entomology

PAULA RIVADENEIRA

Assistant Specialist, Food Safety and Wildlife

SHUJUAN (LUCY) LI

Assistant in Extension, Public Health Integrated Pest Management

CONTACT:

DAWN H. GOUGE

dhgouge@email.arizona.edu

**This information has been reviewed
by University faculty.**

extension.arizona.edu/pubs/az1784-2018.pdf

**Other titles from Arizona Cooperative Extension
can be found at:**

extension.arizona.edu/pubs

Any products, services or organizations that are mentioned, shown or indirectly implied in this publication do not imply endorsement by The University of Arizona.

Issued in furtherance of Cooperative Extension work, acts of May 8 and June 30, 1914, in cooperation with the U.S. Department of Agriculture, Jeffrey C. Silvertooth, Associate Dean & Director, Extension & Economic Development, Division of Agriculture, Life and Veterinary Sciences, and Cooperative Extension, The University of Arizona.

The University of Arizona is an equal opportunity, affirmative action institution. The University does not discriminate on the basis of race, color, religion, sex, national origin, age, disability, veteran status, sexual orientation, gender identity, or genetic information in its programs and activities.